

# Predicting the Ideal Implant Size Before Enucleation

Sara A. Kaltreider, M.D., Jeffrey L. Jacobs, M.D., and Michael O. Hughes, C.O.

*Department of Ophthalmology, University of Virginia, Charlottesville, Virginia, U.S.A.*

---

**Purpose:** This study of volume replacement in anophthalmic sockets compares the volume replaced by the implant and prosthesis with the volume removed from the socket and evaluates A-scan ultrasonography as a tool to predict an ideal implant size before enucleation.

**Methods:** In this retrospective study of 59 anophthalmic patients, the volume replaced by the implant and the prosthesis was compared with the volume of the enucleated eye. The volume removed was estimated by calculating the volume of the fellow eye using A-scan ultrasonography. Enophthalmos and superior sulcus deformity were measured and correlated with the percent volume replacement in the anophthalmic sockets.

**Results:** Greater enophthalmos and superior sulcus deformity were found in patients with less than 100% volume replacement compared with those with 100% or more volume replacement. The axial length determined by A-scan ultrasonography of the fellow eye suggested that a larger implant size should have been placed in 76.3% of those patients with less than 100% volume replacement. Sixty-three percent of adult patients could have received an implant more than 22 mm in diameter to fill 80% of the volume removed at enucleation.

**Conclusions:** A-scan ultrasonography of the fellow eye provides a useful tool for predicting the implant size before surgery for optimal volume replacement.

---

Enophthalmos and superior sulcus deformity, clinical stigmata of insufficient volume replacement in the anophthalmic socket, are problems that have been approached retrospectively by placing various materials to provide additional volume in the upper eyelid, the superior extraconal space, or the subperiosteal space inferiorly (1-11). These procedures improve, but often do not completely correct, the superior sulcus defect and enophthalmos, and subject the patient to the morbidity of additional lid and orbital surgery.

An analysis of volume replacement after enucleation must take into account the volume of the implant(s), the volume of the prosthesis, the symmetry or asymmetry of the bony orbits, and the ability of the socket to accommodate the implant and prosthesis (presence or absence of socket contraction). We

assume that the best time for volume replacement is at the time of enucleation and that, under most circumstances, the best place for volume replacement is within the extraocular muscle cone.

This study was designed to retrospectively examine volume replacement in anophthalmic sockets, to observe the relationship of the percent volume replacement with the amount of enophthalmos and superior sulcus deformity, and to determine if the preoperative use of A-scan ultrasonography to predict appropriate implant size can preclude insufficient volume replacement and its associated clinical deformities.

## MATERIALS AND METHODS

Fifty-nine patients with 72 implant and prosthetic combinations were studied. The patients were divided into three groups: group 1, pediatric patients ( $n = 5$ ); group 2, adults who underwent enucleation with placement of an implant in childhood ( $n = 16$ ); and group 3, adults who underwent enucleation in adulthood ( $n = 38$ ).

Accepted September 11, 1998.

Address correspondence and reprint requests to Dr. Sara A. Kaltreider, P. O. Box 10009, University of Virginia Health System, Charlottesville, VA 22906-0009, U.S.A.

**TABLE 1.** Implant diameter required to replace 70% and 80% of volume removed, based on A-scan of remaining eye

A-scan (mm)*	Implant diameter to replace	
	70%	80%
20.0	18.5	19.5
20.5	19.0	20.0
21.0	19.5	20.5
21.5	20.0	21.0
22.0	20.5	21.0
22.5	21.0	21.5
23.0	21.5	22.0
23.5	22.0	23.0
24.0	22.0	23.5
24.5	22.0	23.5
24.5	22.5	23.5
25.0	23.0	24.0
25.5	23.5	24.5
26.0	24.0	25.0
26.5	24.5	25.5
27.0	25.0	25.5
27.5	25.5	26.0
28.0	25.5	26.5
28.5	26.0	27.0

\*Axial length of the enucleated eye measured with calipers during surgery minus 1 mm may be used in place of A-scan measurement in those patients in whom A-scan of the fellow eye is not possible.

### Calculations

- Volume ( $V$ ) replacement =  $V_{\text{implant}} + V_{\text{prosthesis}}$ .  $V_1$  = initial volume replacement.  $V_2$  = volume replacement after secondary implant.
- $V$  spherical implant =  $\frac{4}{3}\pi r^3$ 
  - $V$  subtracted from implant by flattening anterior surface =  $\pi(Ar^2 - Ar^3/3)$
  - $r = \frac{1}{2}[\text{diameter } (D) \text{ of spherical implant}]$
  - $r$  (scleral-wrapped sphere) =  $\frac{1}{2}(D \text{ implant} + 1 \text{ mm})$ . The scleral wrap was incomplete and the thickness of the sclera less than 1 mm in some areas. Therefore, the above formula for  $r$  was the closest approximation.
  - $V$  of aspherical implants was determined by volume displacement
- $V$  prosthesis =  $V$  displaced by an alginate cast of the prosthesis
- Estimated  $V$  removed =  $\frac{4}{3}\pi r^3$ ,  $r = \frac{1}{2}(A\text{-scan} + 1 \text{ mm})$ . This estimation assumes that the volume of the enucleated eye is equal to the volume of the remaining eye. This assumption is not true in cases of buphthalmos, microphthalmos, severe anisometropia, phthisis, and severely traumatized eyes. With the exception of these cases, however, the A-scan of the fellow eye provides a reasonable estimate of the premorbid axial length of the enucleated eye.
- $\%V$  replacement =  $V \text{ replacement} / V \text{ removed} \times 100$ 
  - $\%V$  implant =  $V \text{ implant} / V \text{ replacement} \times 100$
  - $\%V$  prosthesis =  $V \text{ prosthesis} / V \text{ replacement} \times 100$
- The implant diameter required to replace 70% to 80% of volume removed (estimated by A-scan of fellow eye) was calculated and tabulated in Table 1. The volume to be filled by the prosthesis was arbitrarily chosen to be 20% to 30%, which consistently allows sufficient thickness of the prosthesis for integration with porous implants, provided the implant is not anteriorly malpositioned.
- The appearance score was the difference between exophthalmometry readings plus the superior sulcus rating on a scale of 0 to 4.
  - 0 = none
  - 1 = trace, barely detectable
  - 2 = mild, easily detectable, medial only
  - 3 = moderate, obvious, medial to lateral
  - 4 = severe, deep, medial to lateral

## RESULTS

### Group 1

The average volume replacement in children was 79.8%. This volume was distributed with 70.6% of the volume in the implant and 29.4% in the prosthesis. None of these patients had severe superior sulcus deformity or severe enophthalmos. One patient had 1 mm of proptosis and an anteriorly malpositioned implant with a small area of implant exposure. A-scan ultrasonography suggested that a larger implant could have been placed in all four patients who received less than 100% volume replacement. The A-scan predicted range of implant diameter was 18.5 mm to 22 mm.

### Group 2

The average volume replacement in the 16 adult patients who had undergone enucleation in childhood was 86.5%, with 37.5% of the volume in the prosthesis. Figure 1 shows the distribution of patients in each range of volume replacement.

Four patients with mild to moderate socket contraction had an average volume replacement of 89.6%, with 35.7% of the volume in the prosthesis. All of these patients had mucous membrane grafting to reconstruct the anterior socket. The remaining 12 patients with noncontracted sockets had 85.5% volume replacement, with 38.1% in the prosthesis. One patient had proptosis, a volume replacement of 95.5%, and an anterior implant.

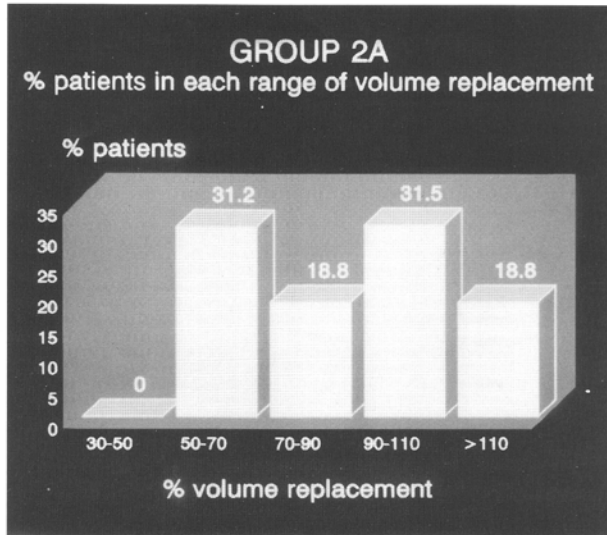


FIG. 1. Group 2: distribution of patients in each range of volume replacement.

The largest implant diameter suggested by A-scan ultrasonography was 24 mm and the smallest was 19 mm. Of the 16 patients, 12.5% could have accommodated a sphere more than 22 mm diameter to replace 70% of the volume removed at enucleation, leaving 30% to be filled by the prosthesis. Of the 16 patients, 56.2% of the sockets could have received a sphere more than 22 mm in diameter for 80% volume replacement by the implant, leaving 20% to be filled by the prosthesis.

The A-scan result suggested a larger implant for 75% of patients, including three patients with more than 100% volume replacement and large prosthetics augmented to correct the upper lid position. In none of the patients with less than 100% volume replacement and optimal prosthesis did the A-scan result fail to detect the need for a larger implant.

A better appearance score was associated with increased volume replacement. The mean appearance score for those patients with less than 100% volume replacement was 3.5, whereas the mean appearance score for those patients with 100% volume replacement or more was 1.

#### Patient 1

A 40-year-old patient who had undergone enucleation of the right eye at age 2 years had an exposed, mesh-covered implant and socket contraction. The A-scan result of the left eye was 23.99 mm. The patient underwent removal of the original implant, placement of a hydroxyapatite implant, and mucous membrane grafting (Fig. 2).

$V$  removed = 8.17 ml

$V_1$  replaced = 1.27 ml (aspherical implant) + 4.2 ml (prosthesis) = 5.47 ml

$V_2$  replaced = 7.79 ml (20-mm implant) + 3.6 ml (prosthesis) = 7.79 ml

The percentage volume replacement increased from 66.9% with the primary implant to 95.3% with the secondary implant. The superior sulcus deformity improved from severe (4+) to none, and the enophthalmos improved from 2 mm to none.

#### Group 3

The patients in group 3 had an average volume replacement of 97.4%. Figure 3 shows the distribution of patients in each range of volume replacement. On average, 70.2% of the volume was in the implant and 29.8% was in the prosthesis. The minimum implant diameter suggested by the A-scan result was 19.5 mm, and the maximum was 27 mm in two patients with high myopia who had A-scan results of 28.46 mm and 28.30 mm.

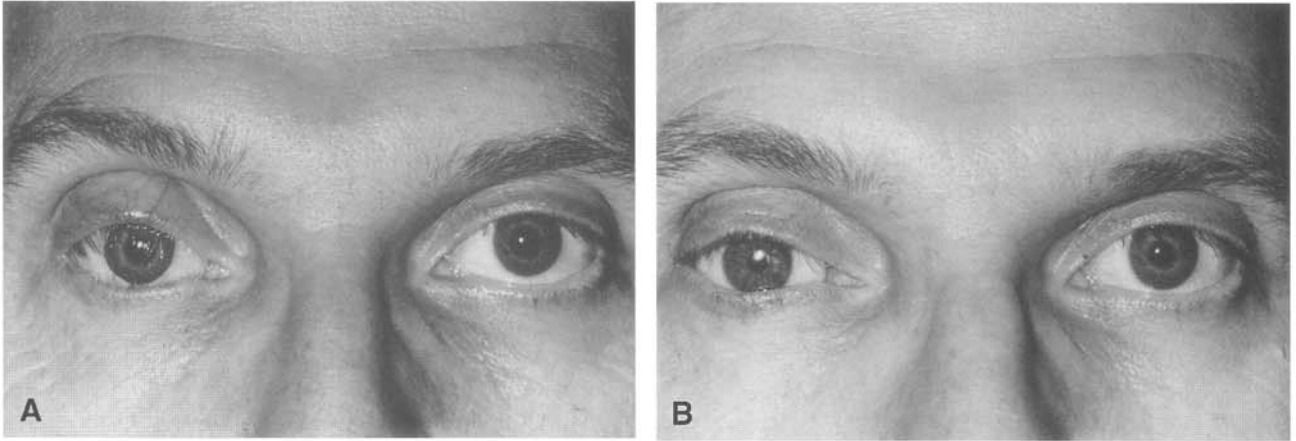
In this group, 44.7% of patients had less than 100% volume replacement, and the A-scan result suggested the use of a larger implant in 76% of these patients. In the remaining 24% of patients with less than 100% volume replacement, the A-scan result did not suggest a larger implant. The following factors precluded a larger prosthesis: socket contraction, persistent chemosis with a small prosthesis, and anteriorly placed implants. These patients had volume replacements ranging from 92.0% to 96.8%.

The A-scan result suggested a larger implant in 19.0% of patients with more than 100% volume replacement. All of these patients had blepharoptosis with large prostheses that had been augmented superiorly. The average volume replacement in the prosthesis was 39.6% compared with an average of 27.0% for those patients with more than 100% volume replacement and no blepharoptosis.

The average appearance score of patients with less than 100% volume replacement was 4.4, compared with a score of 2.6 in patients with more than 100% volume replacement.

#### Patient 2

Patient 2 underwent enucleation for a blind right eye after trauma. The A-scan result of the fellow eye was 24.18 mm and suggested that an implant size of 22 mm to 23.5 mm could be accommodated in the socket (Fig. 4).



**FIG. 2.** **A.** This patient has volume replacement of 66.9%, severe (4+) superior sulcus deformity, and 2-mm enophthalmos. **B.** After secondary implant and mucous membrane grafting, he has no superior sulcus deformity, no enophthalmos, mild ptosis, and a volume replacement of 95.3%.

$V$  removed = 8.36 ml  
 $V$  replaced = 6.23 ml (22-mm scleral-wrapped implant) + 2.50 ml (prosthesis) = 8.73 ml  
 $\%V$  replacement = 104.4%

She has trace superior sulcus deformity and no enophthalmos.

In some circumstances, a 22-mm implant is not adequate, as illustrated by patient 3.

#### Patient 3

Patient 3 had high myopia with an A-scan result of 28.46 mm underwent enucleation of a blind painful left eye. Theoretically, he could have accommodated a 26 mm to 27 mm implant (Fig. 5).

$V$  removed = 13.39 ml  
 $V$  replaced = 6.47 ml (22-mm scleral-wrapped implant) + 1.90 ml (prosthesis) = 8.27 ml  
 $\%V$  replaced = 61.8%

This patient has 2-mm enophthalmos and no superior sulcus deformity.

Patients with anteriorly placed implants and more than 100% volume replacement may have superior sulcus deformity and proptosis, as illustrated by patient 4.

#### Patient 4

A 22-mm scleral-wrapped implant was placed in the left socket. A-scan results of the right eye showed 20.78 mm, suggesting a maximum implant diameter of 20.5 mm (Fig. 6).

$V$  removed = 5.41 ml

$V$  replaced = 6.07 ml (22-mm scleral-wrapped implant) + 0.75 ml (prosthesis) = 6.82 ml  
 $\%V$  replaced = 126%

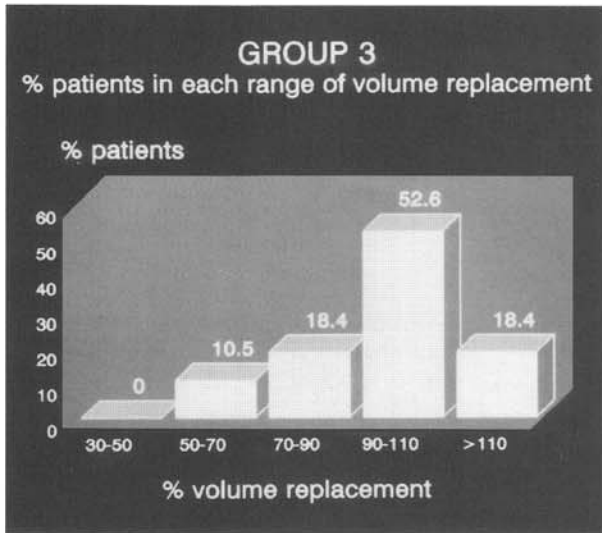
The patient subsequently underwent transposition flap from the inferior fornix to cover an exposed, anteriorly malpositioned implant. She had a severe superior sulcus deformity despite overcorrection of the volume removed. A 20-mm implant placed posteriorly in the socket would have been sufficient.

Table 2 summarizes key data from groups 1, 2, and 3.

## DISCUSSION

This study and that of Thaller (13) demonstrate that most anophthalmic sockets are likely volume deficient, and, as a result, enophthalmos and superior sulcus deformity develops that is probably unrelated to fat atrophy (12). We believe that superior sulcus deformity and enophthalmos should not be attributed to fat atrophy unless 100% of the volume removed at enucleation has been replaced.

Although many factors other than implant volume and prosthesis volume either enhance or limit soft tissue replacement, these two factors may be directly controlled by the surgeon and the ocularist. The adequacy or inadequacy of the implant size and position may adversely affect what the ocularist can do to enhance volume replacement. A severe superior sulcus deformity cannot be eliminated by increasing the bulk of the prosthesis. Similarly, enophthalmos may not be completely corrected without producing lagophthalmos and downward displacement of the lower lid.



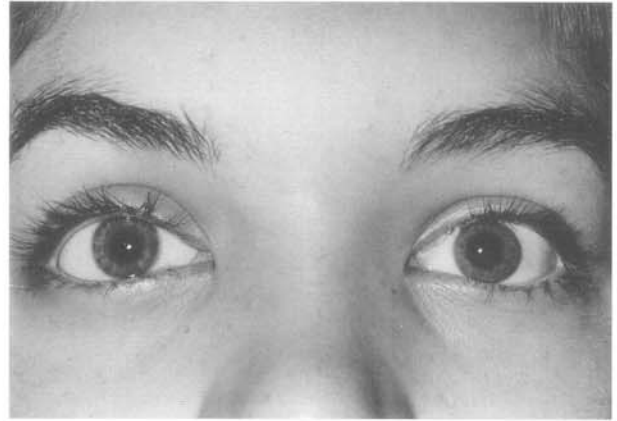
**FIG. 3.** Group 3: distribution of patients in each range of volume replacement.

Factors influencing the soft tissue volume and bony structures (bony orbital volume) include previous surgery, previous trauma, congenital deformity, sinus disease, and socket contraction. For most patients, however, replacing the volume that is removed at enucleation will produce good results.

Early efficient volume replacement in pediatric patients may prevent the problems observed in group 2 patients. Even mild to moderate socket contraction in group 2 patients did not seem to impair volume replacement (89.6%), commensurate with volume replacement in noncontracted sockets (85.5%).

Our study demonstrates that the A-scan is a valuable tool in estimating an appropriate sphere diameter in adults (groups 2 and 3), and would have prevented undercorrection associated with superior sulcus deformity and enophthalmos in 76.3% of patients. Appropriate sphere size would have prevented oversized prosthetics and distortion of the lids, which occurred in three patients in group 2 and four patients in group 3 with blepharoptosis and more than 100% volume replacement. A preoperative A-scan of the fellow eye would have suggested placing a larger implant in all of these patients.

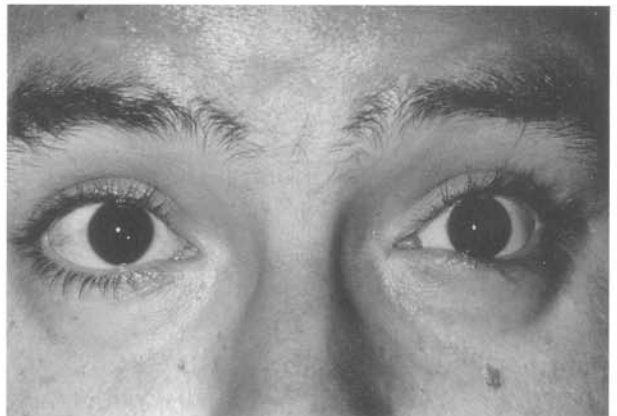The A-scan would have prevented two patients from receiving oversized implants, one patient in group 1, and one patient in group 3. In only one patient did the A-scan fail to suggest the use of a larger implant in a patient with severe clinical vol-



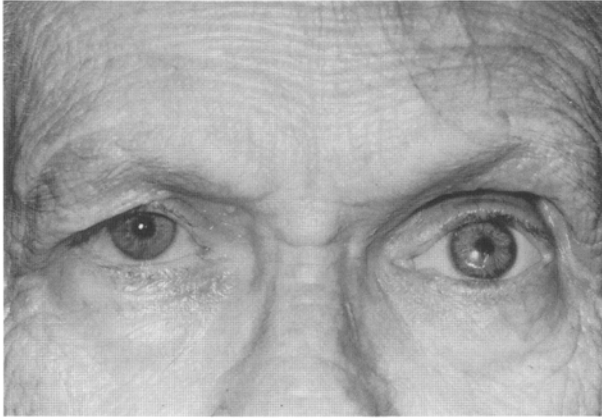**FIG. 4.** This patient has 104.4% of the right eye volume replaced, trace superior sulcus defect, and no enophthalmos.

ume deficiency despite 119.0% volume replacement.

The authors recommend a preoperative A-scan and placement of an implant with an appropriate diameter (Table 1) to replace 70% to 80% of the volume removed. Sizer spheres may be used to confirm the implant diameter, but are not recommended as a precise guideline. Too often, a fear of implant exposure limits the diameter of implant used, even though increasing implant size has been shown not to correlate with incidence of exposure (14,15). Direct measurement of the enucleated specimen may not be an accurate guideline to implant selection because of antecedent disease or surgery that may change the axial dimension of the eye. However, intraoperative measurement of the axial length with calipers may be valuable in those



**FIG. 5.** This patient with high myopia has only 61.8% volume replacement, 2-mm enophthalmos, and no superior sulcus deformity. The implant was placed as far posteriorly as possible to allow optimal volume augmentation of the prosthesis.



**FIG. 6.** This patient has a 22-mm anteriorly malpositioned implant, a history of reconstruction with flaps, and a mucous membrane graft for exposure of the implant. A-scan result indicated that a 20-mm implant should have sufficed. She has a severe superior sulcus deformity and a very thin prosthesis.

patients undergoing enucleation for intraocular tumor or nonphthisical blind eyes.

Pediatric patients (group 1) may not cooperate for an A-scan measurement, although three of five patients in this study were cooperative and one underwent an A-scan while having a retinal examination under general anesthesia. In these patients, direct measurement of the axial length of the specimen during surgery would be helpful because most pediatric enucleations involve an eye of normal size. Most enucleations in pediatric patients occur at approximately age 2 years for retinoblastoma or trauma, and the eye has reached 85% to 90% of its adult size at this time (16). Theoretically, one could replace 80% to 90% of the volume removed at enucleation and still have adequate space anteriorly for the prosthesis and have potential for augmentation later. This may fail to provide enough volume for those who experience axial myopia later in life, but it would provide a guideline for the minimum volume replacement. Therefore we recommend a preoperative A-scan in pediatric patients and measure-

ment of the diameter of the enucleated eye in the operating room as guidelines for implant size (referring to Table 1), substituting direct measurement of the axial length of the specimen minus 1 mm for the A-scan when the A-scan is not feasible.

Subjectively, superior sulcus deformity is more noticeable than enophthalmos. Superior sulcus deformity is less prominent when the implant is placed more posteriorly in the muscle cone. This is demonstrated by comparing Figure 6, one of only two patients in this study who received an implant larger in diameter than the A-scan would have suggested, with Figure 5, a patient with high myopia and only 61.8% volume replacement. One may consider volume replacement from the posterior to the anterior direction, first filling the posterior aspect of the orbit maximally, then filling the anterior compartment with the prosthesis. Deficiencies in the posterior compartment are not totally correctable by augmenting the prosthesis, but are more readily managed with prosthetic augmentation and lid surgery if the implant is placed posteriorly.

Two thirds of the patients in this study might have accommodated a sphere diameter larger than 22 mm to optimize volume replacement. A 22-mm sphere implant, however, may not provide adequate volume to eliminate superior sulcus deformity and enophthalmos in trauma patients, patients with high myopia, patients in whom the implant is placed anteriorly, and a few patients with no history of trauma, myopia, or sinus disease (patients 3 and 4; Figs. 5 and 6). Additionally, implants larger than 22 mm in diameter are not routinely supplied by manufacturers.

## REFERENCES

- Hill JC, Radford CJ. Treatment of advancing enophthalmos. *Am J Ophthalmol* 1965;60:487-92.
- Smith B, Obear M, Leone CR. The correction of enophthalmos associated with anophthalmos by glass bead implantation. *Am J Ophthalmol* 1967;64:1088-93.
- Spivey BE, Allen L, Stewart WB. Surgical correction of superior sulcus deformity occurring after enucleation. *Am J Ophthalmol* 1972;82:365-70.
- Vistnes LM, Paris GL. Uses of RTV silicone in orbital reconstruction. *Am J Ophthalmol* 1977;83:577-81.
- Smith B, Petrelli R. Dermis-fat graft as a movable implant within the muscle cone. *Am J Ophthalmol* 1978;85:62-6.
- Linberg JV, Anderson RL, Edwards JJ, et al. Preserved irradiated homologous cartilage for orbital reconstruction. *Ophthalmic Surg* 1980;11:457-62.
- Soll DB. The anophthalmic socket. *Ophthalmology* 1982;89:407-23.
- Smith B, Lisman RD. Use of sclera and liquid collagen in the camouflage of superior sulcus deformities. *Ophthalmology* 1983;90:230-5.

**TABLE 2.** Summary of data for groups 1, 2, and 3

Group	% Volume replaced	% Volume implant	% Volume prosthesis	% Patients requiring	
				Larger implant for 70% replacement	>22-mm implant for 80% replacement
1	79.8	70.6	29.4	80	0
2	86.5	62.5	37.5	75	56.2
3	97.4	70.2	29.8	76	65.8

9. Van Gemert JV, Leone CR. Correction of a deep superior sulcus with dermis-fat implantation. *Arch Ophthalmol* 1986;104:604-7.
10. Cahill KV, Burns JA. Volume augmentation of the anophthalmic orbit with cross-linked collagen. *Arch Ophthalmol* 1989;107:1684-6.
11. Cowen DE, Antonyshyn O. The vascularized temporoparietal fascial flap for correction of the deep superior sulcus. *Ophthalmic Plast Reconstr Surg* 1995;11:100-8.
12. Kronish JW, Gonnering RS, Dortzbach RK, et al. The pathophysiology of the anophthalmic socket. Part II. Analysis of orbital fat. *Ophthalmic Plast Reconstr Surg* 1990; 6:88-95.
13. Thaller VT. Enucleation volume measurement. *Ophthalmic Plast Reconstr Surg* 1997;13:18-20.
14. Kaltreider SA, Newman. Prevention and management of complications associated with the hydroxyapatite implant. *Ophthalmic Plast Reconstr Surg* 1996;18-31.
15. Nunery W, Heinz GW, Bonnin JM, et al. Exposure rate of hydroxyapatite spheres in the anophthalmic socket histopathologic correlation and comparison with silicone sphere implants. *Ophthalmic Plast Reconstr Surg* 1993; 9(2):96-104.
16. Weiss AH, Kousseff BG, Ross EA, Longbottom J. Complex microphthalmos. *Arch Ophthalmol* 1989;107:1619-24.